

Visibility of Puncture Sites After External Osteotomy in Rhinoplastic Surgery

Anthony E. Hinton, FRCS; Terry Hung, FRCS; Hamid Daya, FRCS; Michael O'Connell, FRCS

Background: External lateral osteotomy performed through a small puncture incision in the skin has numerous advantages, but it has been criticized by its opponents who claim it may leave visible scars.

Objective: To examine whether the external lateral osteotomy actually leaves visible scars.

Methods: Eighty-one postoperative photographs of patients who had undergone the external lateral osteotomy technique were reviewed. The photographic slides were a mixture of some taken 3 months after surgery and

others taken 6 months after surgery. Scar visibility was assessed.

Results: Percutaneous puncture site visibility as assessed by 3 surgeons independently was 0% at 6 months after surgery and about 3% at 3 months after surgery.

Conclusion: The external osteotomy procedure produces an excellent cosmetic result at the puncture sites in the skin.

Arch Facial Plast Surg. 2003;5:408-411

THE PURPOSE of using osteotomies in rhinoplastic surgery is to mobilize the nasal bones to produce the desired effect with the least morbidity. Methods of performing the lateral osteotomy in rhinoplastic surgery may broadly be divided into internal and external techniques (**Figure 1**). Internal techniques include using a curved Neivert osteotome, performing microosteotomies through an intranasal incision, or using a Joseph saw.¹ More rarely used techniques have included the use of electric saws and cutting forceps.² One of the earliest reports of the use of a percutaneous external lateral osteotomy approach was by Weir in 1892,³ who used a percutaneous chisel osteotomy or nasal forceps to infracture the lateral nasal wall (**Figure 2**).

The external lateral osteotomy performed through a small puncture incision in the skin has numerous advantages (Tony R. Bull, FRCS, written communication, 1995). It allows great precision in the placement of the osteotomy, it gives scope for marked narrowing of the nose, and it may be used to make intermediate osteotomies that allow straightening of

sharply curved nasal bones.⁴ Finally, it may also be used for the delayed refracture technique in patients presenting late with a fractured nose. Opponents of the percutaneous external lateral osteotomy technique claim that it may leave visible scars. The aim of this study was to examine the validity of this criticism.

METHODS

Eighty-one postoperative photographs of patients who had undergone the external lateral osteotomy technique at either the Royal National Throat, Nose, and Ear Hospital or St George's Hospital, London, England, were reviewed independently by 3 otolaryngologists, each with training in plastic surgery and each with a special interest in rhinoplastic surgery. The photographic slides were a mixture of some taken 3 months after surgery and others taken 6 months after surgery. These 35-mm slides were projected at life size and at original magnification $\times 100$. Scar visibility for each of the 4 puncture sites in the frontal, lateral, and tip views was assessed. A total of 540 possible visible puncture sites (frontal, lateral, or tip views) were examined by each of the 3 surgeons. Each puncture site was first examined from a distance of 1 m at a life-size magnification. A scar was recorded as either visible or not visible. The exercise was then

From the Department of Otolaryngology, St George's Hospital, London, England.




Figure 1. Percutaneous osteotomy locations. Osteotomies may be lateral (L), superior (S), intermediate longitudinal (IL), or intermediate transverse (IT).

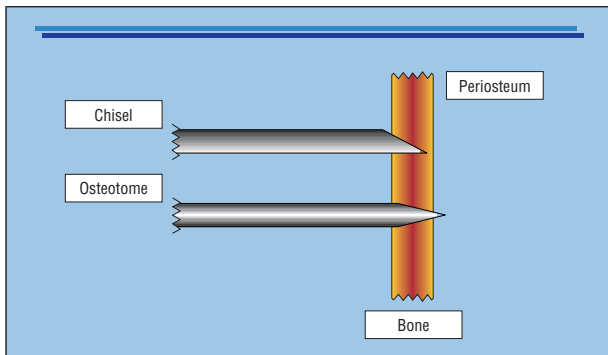


Figure 2. Use of chisel vs osteotome for percutaneous osteotomies. Use of an osteotome instead of a chisel makes it easy to perforate the periosteum on the inner surface of the nasal bone and should be avoided.

repeated from an observer distance of 1 m but with the projected slide magnified $\times 100$.

RESULTS

A total of 540 puncture sites were examined by each surgeon for puncture site visibility. Of the patients, 37% were male ($n=30$) and 63% were female ($n=51$). Seventy percent of the photographs were taken at 3 months and 30% were taken at 6 months.

Puncture site visibility at 3 months, looking at slides at life-size projection, was greatest for surgeon 3, at 6%. Projected at original magnification $\times 100$, the scar visibility was greatest for surgeons 2 and 3, at 9% each (**Figure 3**).

Puncture site visibility at 6 months at life-size projection was 0% for all 3 surgeons. Projected at original magnification $\times 100$, scar visibility was greatest for surgeon 2, at less than 3% (**Figure 4**).

Agreement on puncture site visibility between surgeons was poor. At least 2 of 3 surgeons agreed that a puncture site was visible at 3 months in less than 3% of cases projected at life size and 7% of cases projected at original magnification $\times 100$. All 3 surgeons agreed that a puncture site was visible at 3 months in less than 3%

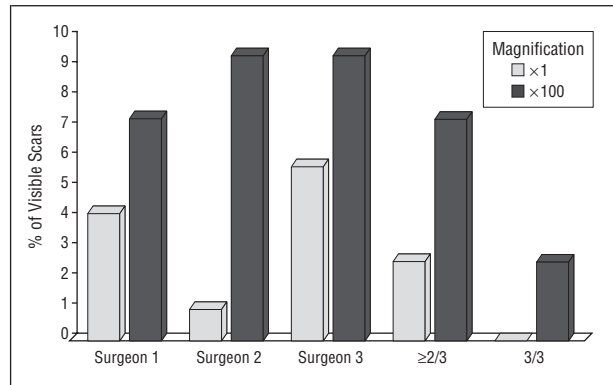


Figure 3. Puncture site visibility 3 months after surgery with slides viewed at life size and original magnification $\times 100$.

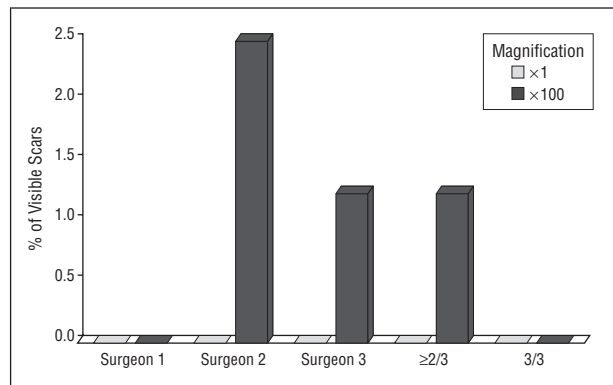


Figure 4. Puncture site visibility 6 months after surgery with slides viewed at life size and original magnification $\times 100$.

of cases projected at original magnification $\times 100$. All 3 surgeons could not agree any puncture site was visible at 3 months in any case projected at life size (Figure 1).

At least 2 of 3 surgeons could agree on puncture site visibility at 6 months in 1% of the cases projected at original magnification $\times 100$. No 2 of the 3 surgeons could agree on scar visibility in any case when the same cases were projected at life size. On reviewing the slides taken 6 months after surgery, all 3 surgeons could not agree any puncture site was visible at all at either life size or at original magnification $\times 100$ (Figure 2).

An example of a visible site after 3 months agreed on by at least 2 surgeons is shown in **Figure 5**. Puncture sites with no scarring visible to any surgeon at original magnification $\times 100$ are shown in **Figure 6**.

COMMENT

The external lateral osteotomy performed through a small puncture incision in the skin has several advantages. It allows great precision in the placement of the osteotomy, and it gives scope for marked narrowing of the nose. The narrowing does not affect the nasal valve or compromise the airway.⁵ An intermediate longitudinal osteotomy may be used to increase the narrowing along the nasal dorsum. The external percutaneous approach may also be used to make intermediate transverse osteotomies that can be used to straighten sharply curved nasal bones. If 2 banana-shaped nasal bones are mobilized

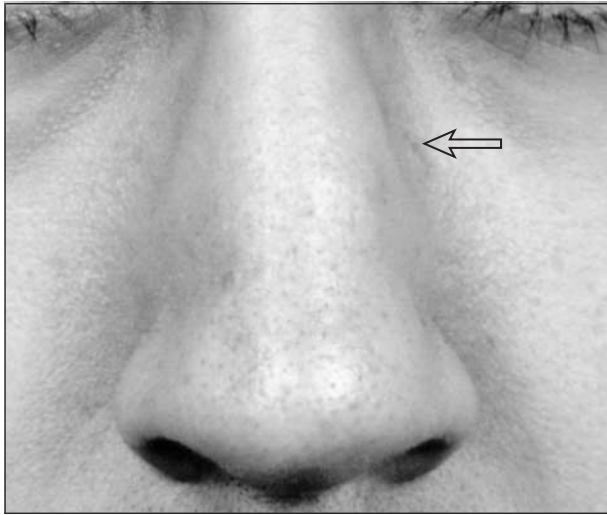


Figure 5. A visible puncture site (arrow) 3 months after surgery.

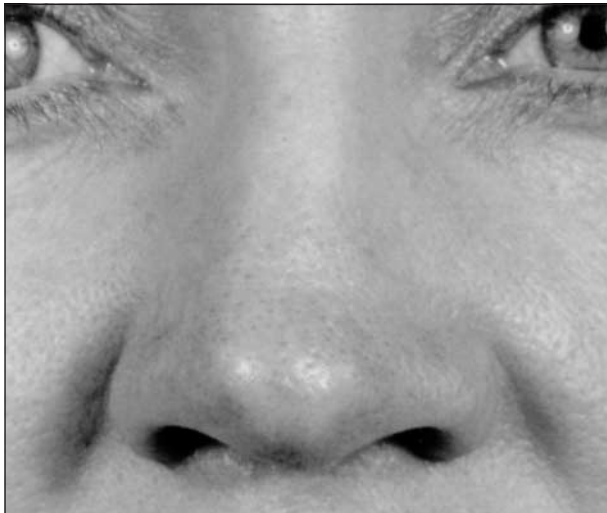

Figure 6. Puncture sites with no scarring visible to any surgeon at original magnification $\times 100$.

with superior, lateral, and medial osteotomies, there still remain 2 sharply curved nasal bones. If, however, transverse intermediate osteotomies are performed first, this results in 2 half nasal bones on each side of the nose, each piece of the bone with a lesser curve than the whole bone. Much overall straightening of the nasal skeleton results. Finally, external osteotomy may also be used for the delayed refracture technique in patients presenting late with a fractured nose. Nasal bones after a fracture start to fix with callus by 2 weeks, and after this time manipulation, either digital or with instruments, may be impossible. By using superior and lateral external osteotomies, the nasal bones can be mobilized and corrected successfully by manipulation sometimes up to 6 weeks after trauma. Very occasionally, grossly thickened nasal bones can interfere with the percutaneous external lateral osteotomy technique (**Figure 7**).

The criticism of the percutaneous external lateral osteotomy technique is that it may leave visible scars and can also lead to aesthetically unacceptable bruising if the angular vessels are traumatized. In the present

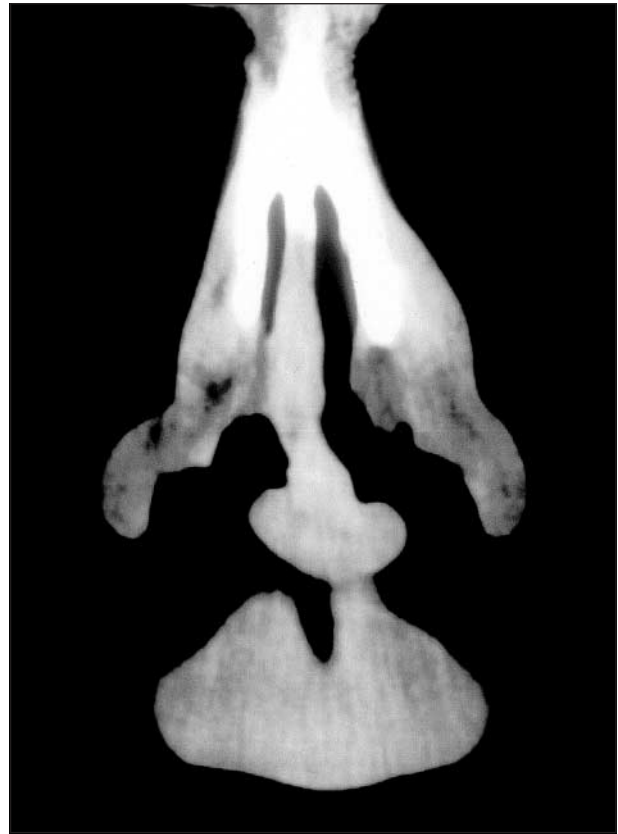


Figure 7. Grossly thickened nasal bones, which can interfere with the percutaneous external lateral osteotomy technique.

study, we have shown that percutaneous puncture site visibility as assessed by 3 surgeons independently was 0% at 6 months after surgery. No patients in the study commented on the puncture sites either immediately after surgery or after external splint removal 1 week after surgery. Subjectively, our experience is that the percutaneous external lateral osteotomy technique causes less bruising than other methods of performing a lateral osteotomy. Keloid formation in dark-skinned races does not appear to be a problem in the middle third of the face (Tony R. Bull, FRCS, written communication, 1995), but it is a theoretical possibility that should be considered preoperatively when this technique is used.

Experimental evidence examining the results of different lateral osteotomy techniques on cadavers has shown that, although the percutaneous external lateral osteotomy technique produces an irregular osteotomy margin, this method resulted in minimal disruption of the periosteum and very little injury to the nasal mucosa. The percutaneous technique was simple to perform, gave consistent results, and resulted in increased stability of the infractured segment of nasal bone.¹ As no periosteal pocket is raised that could collect blood, the likelihood of severe ecchymosis is reduced. The intact areas of periosteum between the perforations act to stabilize the fractured bones.⁶ A further study comparing the perforating lateral osteotomy and the sliding subperiosteal lateral osteotomy showed that using the perforating technique gave a more stable bony vault, greater contact of all soft tis-

sues to the bone, less dead space along the osteotomy, less airway compromise, and no subluxation of the nasal bones.⁷

No previous studies have looked specifically at the visibility of puncture sites from the use of the percutaneous perforating lateral osteotomy technique, although the procedure itself has been previously reported.^{1,8} It is reassuring that we have confirmed what we expected from our past experience, that no patients are aware of any visibility of the percutaneous puncture sites and, furthermore, 6 months after surgery no experienced rhinoplasty surgeon could detect the puncture sites either.

In conclusion, puncture sites after the percutaneous lateral osteotomy technique are not visible. The external osteotomy procedure has special advantages over other techniques, particularly to narrow the nose, and produces an excellent result at the puncture sites in the skin.

Accepted for publication January 7, 2003.

Corresponding author and reprints: Terry Hung, FRCS, 5 Redcliffe Gardens, London SW10 9BG, England (e-mail: hterryhung@aol.com).

REFERENCES

1. Murakami CS, Larrabee WF. Comparison of osteotomy techniques in the treatment of nasal fractures. *Facial Plast Surg.* 1992;8:209-219.
2. Goldfarb M, Gallups JM, Gerwin JM. Perforating osteotomies in rhinoplasty. *Arch Otolaryngol Head Neck Surg.* 1993;119:624-627.
3. Weir RF. On restoring sunken noses without scarring the face. *N Y J Med.* 1892; 56:449-454.
4. Mackay IS. The deviated nose. *Facial Plast Surg.* 1986;3:253-265.
5. Lund VJ, Bull TR. Rhinoplasty results appraised. *Facial Plast Surg.* 1984;1:157-167.
6. Diamond HP. Rhinoplasty technique. *Surg Clin North Am.* 1971;51:317-331.
7. Ford CN, Battaglia DG, Gentry LR. Preservation of periosteal attachment in lateral osteotomy. *Ann Plast Surg.* 1984;13:107-111.
8. Trenite GJ. Trauma reduction in rhinoplastic surgery. *Rhinology.* 1991;29:111-116.

Call for Images and Quotes

Facial plastic surgery is a visual and artistic specialty. To make the ARCHIVES as interesting and informative as possible, we use the "white space" at the end of articles for images and quotations. Many types of images related to facial plastic surgery are appropriate, eg, research images, photographs of innovative instruments, historical photographs, or interesting clinical pictures. This is an opportunity for all readers of the ARCHIVES to submit. The images require submission in the accepted formats outlined in the "Instructions for Authors" and completion of the usual Author Responsibility Forms. If accepted, they will be published with credit to the individual submitting them. Quotations, particularly those related to facial plastic surgery, are also welcome and will be published with the name of the individual making the quotation.